

REVIEW

Open Access



# Columnar cell lesions of the breast: a practical review for the pathologist

Angela Flavia Logullo<sup>1,2,3\*</sup>  and Cristiane Nimir<sup>2,3</sup>

## Abstract

**Background:** Columnar cell lesions (CCLs) of the breast are characterized by the substitution of regular layer of cuboid epithelial by columnar cells covering the terminal duct lobular units (TDLUs). It also comprises a spectrum of lesions characterized by enlarged TDLUs with variably dilated acini lined by columnar epithelial cells, ranging from one or two layers of benign epithelium to stratified epithelium with atypia. With the increasing use of mammography screening scans in the last 30 years, columnar cell lesions (CCLs) have been diagnosed more frequently, often associated with microcalcifications and abnormal calcifications, requiring breast biopsies. This literature review presents the historical development of this entity description, with many terminologies, the CCLs categories, differential diagnoses, immunohistochemical profile and genetic alterations, reproducibility and clinical implications. In addition it discusses the significance of flat epithelial atypia (FEA), a CCL with low-grade cytological atypia.

**Practical considerations:** FEA are a frequent finding in breast biopsies and should be a warning sign for other possible entities within the lesion area. Since CCLs are an increasingly recognized entity in the diagnostic spectrum of breast proliferative lesions, proper training or tutorials are advisable for general pathologists in order to teach them how to identify CCLs with confidence. Intraductal proliferations with architectural complexities such as cribriform patterns, rigid cellular bridges, and true micropapillary pattern should not fall into the FEA category and are best classified as atypical ductal hyperplasia (ADH) or ductal carcinoma in situ (DCIS).

**Conclusions:** Among CCLs, FEA actually receives more attention due to atypia involved. FEA has been considered a non-obligate pre-neoplastic lesion and progression of these lesions to invasive cancer has been reported as increasingly low (2–7%). Therefore, controversy to the management of those lesions still remains and further intervention is restricted to cases with other premalignant lesions (ADH, DCIS) or in radiologic-pathologic disagreement.

**Keywords:** Columnar cell lesion, CCL, FEA, Breast biopsy

## Definition

Columnar cell lesions of the breast are characterized by the substitution of regular cuboid epithelial layer by columnar epithelial cells covering the terminal duct lobular units (TDLUs) (Schnitt and Vincent-Salomon 2003). With the increasing of mammography screening programs in the last 30 years, columnar cell lesions (CCLs) have been progressively more diagnosed in breast biopsies often performed due to its association with micro calcifications.

Although formally introduced and formally organized as a diagnostic entity by Schnitt and Vicent-Salomon only in 2003 (Schnitt and Vincent-Salomon 2003), CCLs have been there all along. CCLs have been bothering researchers for a long time, such as Dr. John Collins Warren (Warren 1905), who, in 1905, described a lesion as “abnormal involution” in a paper, followed by Dr. Joseph Colt Bloodgood (Bloodgood 1906), who, in 1906, described this proliferation as “adenoid cystic change of senile parenchymatous hypertrophy.” The description of such lesions is identical to CCLs. In 1920, Sir George Lenthal Cheate (Cheate 1920), described the same abnormality as distension of acini, and a population of columnar epithelial cells, and also pointed out the *continuum* to low-grade ductal carcinoma in situ as characteristic of this lesion (Cheate and Cutler 1931). Fifty years of indifference were finally

\* Correspondence: [waitzberg.angela@gmail.com](mailto:waitzberg.angela@gmail.com)

<sup>1</sup>Escola Paulista de Medicina, Universidade Federal de São Paulo, São Paulo, Brazil Departamento de Patologia, Universidade Federal de São Paulo (UNIFESP), Rua Botucatu, 740, São Paulo, SP CEP 04023-062, Brazil

<sup>2</sup>Femme laboratories Rua desembargador Elizeu Guilherme, 200, São Paulo, Brazil

Full list of author information is available at the end of the article



© The Author(s). 2019 **Open Access** This article is distributed under the terms of the Creative Commons Attribution 4.0 International License (<http://creativecommons.org/licenses/by/4.0/>), which permits unrestricted use, distribution, and reproduction in any medium, provided you give appropriate credit to the original author(s) and the source, provide a link to the Creative Commons license, and indicate if changes were made. The Creative Commons Public Domain Dedication waiver (<http://creativecommons.org/publicdomain/zero/1.0/>) applies to the data made available in this article, unless otherwise stated.

interrupted by Wellings et al. (Wellings et al. 1975), when they defined those lesions as “atypical lobules, type A,” and more repercussion was attained by Dr. John G. Azzopardi (Azzopardi 1979) description, using the term “low-grade clinging carcinoma.”

Along these decades, CCLs have been described using many other terminologies, such as “columnar alteration with prominent apical snouts and secretions (CAPSS)”, by Fraser et al., (Fraser et al. 1998) “atypical cystic lobules”, by Oyama et al. (Oyama et al. 1999), “enlarged lobular units with columnar alteration (ELUCA)”, by McLaren et al. (McLaren et al. 2005) and “flat ductal intraepithelial neoplasia (Flat DIN1a)” by Tavassoli (Tavassoli et al. 2003) and Moinfar (Moinfar 2009). The plethora of terms and subtypes is confusing. The existence of multiple terms for this spectrum of lesions impairs the retrospective evaluation concerning patient’s prognosis management and evolution, especially when they are considered to be precursor lesions in the low-grade estrogen-receptor pathways of ductal/lobular neoplasia. A review of the terminology evolution can be found in Table 1.

### Classification of columnar cell lesions

According to Schnitt and Vincent-Salomon’s classification (Schnitt and Vincent-Salomon 2003), CCLs are divided into two main categories, “columnar cell change (CCC)” and “columnar cell hyperplasia (CCH).” When atypia is present, the lesion is further categorized as “columnar cell change with atypia” or “columnar cell hyperplasia with atypia.” These two latter categories were later grouped as “flat epithelial atypia (FEA),” regardless of the presence or absence of hyperplasia.

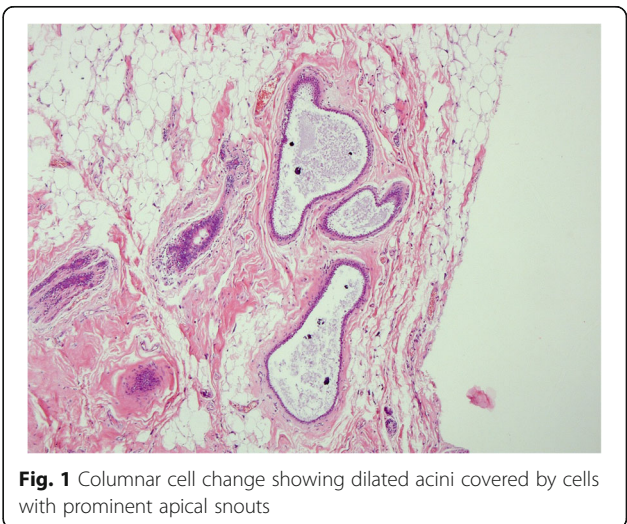
**Table 1** Terminology previously applied to flat epithelial atypia (FEA) of the breast

Terminology	Author	Date
Abnormal involution	John Collins Warren	1905
Adenoid cystic change of senile parenchymatous hypertrophy	Joseph Colt Bloodgood George Lenthal Cheatle	1906 1920
Hyperplastic unfolded lobules	Wellings and Jensen	1975
Low-grade clinging carcinoma	John G. Azzopardi	1979
Columnar alteration with prominent atypical snouts / Columnar cell hyperplasia with atypia	Fraser et al.	1998
Atypical cystic lobules	Oyama	1999
Flat ductal intraepithelial neoplasia	Tavassoli et al. and Farid Moinfar	2003/2009
Columnar cell change (CCC) lesions	Schnitt and Vicent-Salomon	2003
Enlarged lobular units with columnar alteration	McLaren et al.	2005

Columnar cell change is the simplest form of CCL. It is characterized by dilation of the TDLU with epithelium exhibiting tall cells with oval or elongated nuclei orientated perpendicularly to the basement membrane. The nuclei are bland, have fine chromatin, and no visible nucleoli. CCC is also characterized by the presence of secretion, as apical cytoplasmic blebs or snouts, often associated with microcalcifications (Schnitt and Vincent-Salomon 2003; O’Malley et al. 2006; Schnitt 2003a; Schnitt et al. 1992). Proliferation activity is very low in CCC, in the range of 1 to 3%, and most cells show estrogen receptor (ER) expression in immunohistochemistry in a higher amount than adjacent normal breast lobules, probably due to up-regulation of ER. (Dabbs 2012) (Figs. 1 and 2).

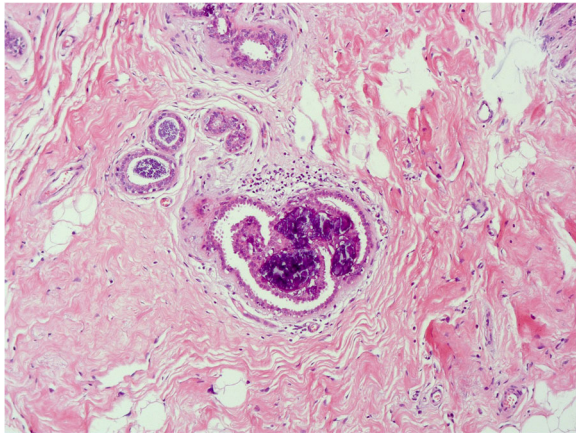
Columnar cell hyperplasia (CCH) without atypia presents the same cytological criteria of CCC but exhibits cell stratification with more than two cell layers, cellular crowding or overlapping and, rarely, small tufts or mounds of cells, but no complex architecture with blunt micropapillary projections (Schnitt and Vincent-Salomon 2003; Schnitt 2003a; Schnitt et al. 1992). Atypia is not present. Similar to CCC, the Ki-67 index is 1 to 3%, and ER expression is upregulated in most cells (Dabbs 2012) (Figs. 3 and 4).

Flat epithelial atypia (FEA) is a term currently used to encompass any CCL with low-grade cytologic atypia (Schnitt 2003b). The term was introduced by the World Health Organization in the 2003 3dition of WHO Classification of Breast Tumors to replace “clinging carcinoma, monomorphous type”, “atypical cystic lobules” and other terms, e.g. “atypical lobules type A”, “atypical columnar change” and “ductal intraepithelial neoplasia 1A” (Tavassoli et al. 2003). It presents as a clonal proliferation, mostly of low cuboidal cells with columnar configuration. These cells are monotonous, with round to oval nuclei (rather than elongated), clearly enlarged, mild



**Fig. 1** Columnar cell change showing dilated acini covered by cells with prominent apical snouts



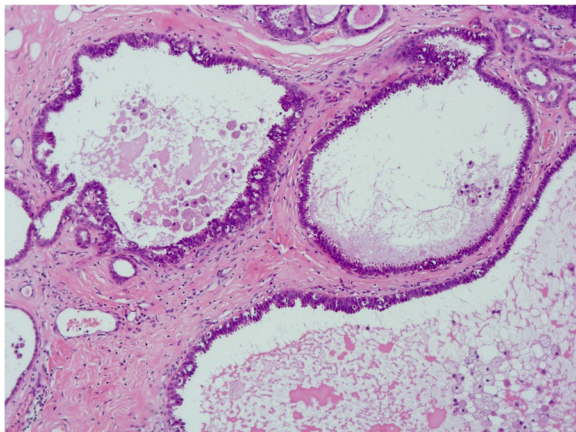


**Fig. 2** Columnar cell change with intraluminal microcalcifications

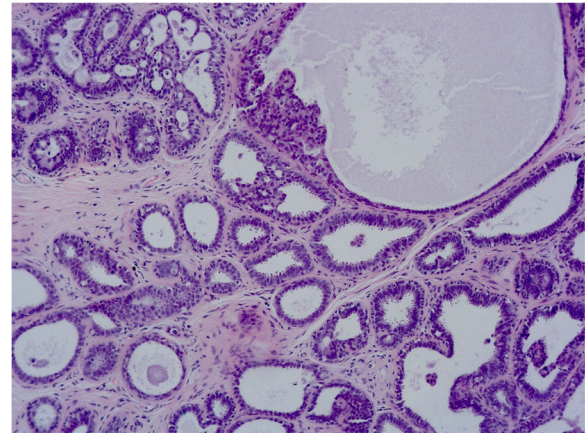
hyperchromasia, increased nuclear-to-cytoplasm ratio and, sometimes, prominent nucleoli with loss of perpendicular orientation to the basement membrane (polarity) (Dabbs 2012; Schnitt 2003b). The cytomorphic features resemble those of the low-grade ductal carcinoma in situ (DCIS). As the lesion proliferates, the cells show stratification, but there are no blunt, micropapillary projections or Roman bridges (Schnitt 2003b). They maintain the flat pattern (Figs. 5, 6 and 7).

#### Differential diagnosis

CCC, CCH and FEA all display irregularly dilated TDLUs, often containing secretion and coarse calcium or granular calcific debris. The FEA nuclei tend to show a more intense blue staining than CCC/CCH reflecting enlarged nuclei and crowded cells. It is important to distinguish FEA from the other CCLs because FEA will require further patient follow-up.



**Fig. 3** Columnar cell hyperplasia showing crowding and pseudostratification of bland nuclei with prominent apical snouts



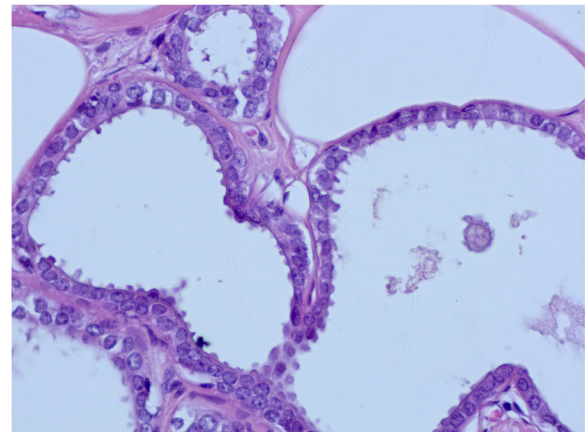
**Fig. 4** Columnar cell hyperplasia showing crowding and pseudostratification of bland nuclei with prominent apical snouts

- **Usual ductal hyperplasia (UDH):**

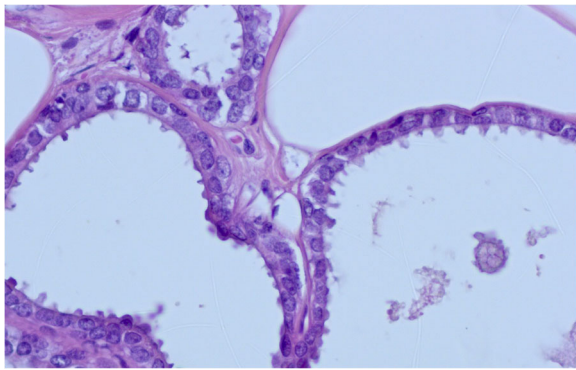
Sometimes, dilated ducts and cystic changes with usual hyperplasia may be confounded with flat atypia. The basal cell line closest to cell membrane may present a columnar feature in UDH which contributes to this diagnostic challenge. However, hyperplastic columnar cells from FEA shows monotonous and hyperchromatic nuclei, contrasting with a streaming and usually elongated nuclei of UDH. Overlapping and piling up of cells is helpful to distinguish UDH from FEA.

- **Apocrine lesions:**

Apocrine metaplasia is one common differential diagnostic entity, showing dilated spaces and calcifications similar to CCC (Hicks and Lester 2016). Besides, it may have a flat or micropapillary growth pattern. The tip here is to recognize the



**Fig. 5** Flat epithelial atypia showing cellular crowding, coarse calcifications and micropapillary tufts



**Fig. 6** Flat epithelial atypia showing cellular crowding, coarse calcifications and, sometimes, apocrine features

low-grade FEA because apocrine metaplasia usually has prominent nucleoli, and peculiar eosinophilic granules, whereas FEA does not (Dabbs 2012).

- **Atypical ductal hyperplasia (ADH) and low-grade DCIS:**

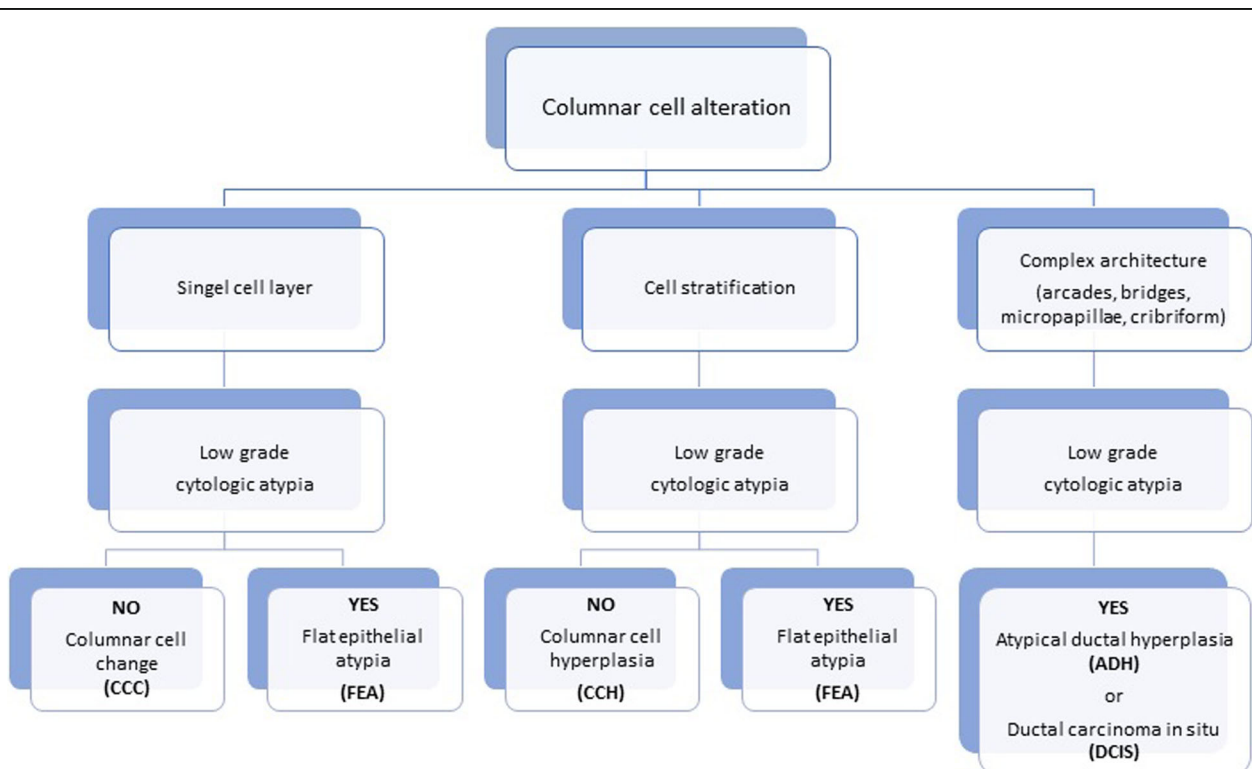
FEA is distinguished from atypical ductal hyperplasia (ADH) and low-grade DCIS by the presence, in ADH/DCIS, of complex architectural patterns like well-developed micropapillae, rigid cellular bridges, bars and arcades (Roman arch) and punched out fenestrations (Figs. 8 and 9).

- **High-grade flat DCIS:**

High-grade cytological atypia with marked nuclear pleomorphism is not a feature of FEA (Hicks and Lester 2016). Such lesions are rarely seen in the absence of high-grade DCIS, with other architectural patterns. Besides that, high-grade DCIS is often HER-2 positive, ER-negative and shows high mitotic index. Otherwise, FEA is HER-2 negative, ER strongly positive and rarely presents mitotic figures.

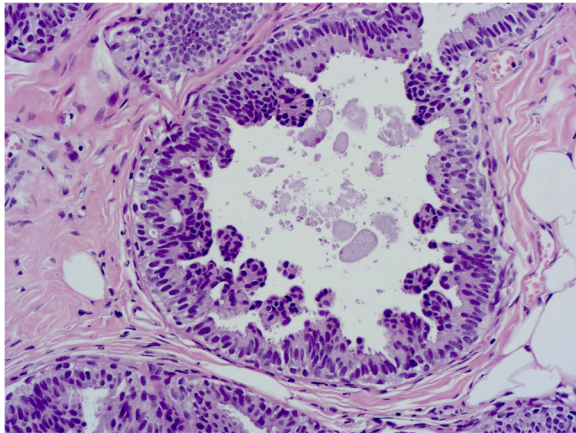
#### Immunohistochemical profile of CCLs

Previous studies evaluated the immunoexpression of several markers in columnar cell changes. These cells are immunoreactive for a broad-spectrum of keratin cocktails, such as AE1/AE3 and CAM 5.2. As luminal layer cells CCLs are negative for the high molecular-weight cytokeratins, such as CK5/CK6 and 34 $\beta$ E-12, and positive for CK8/CK18 and CK19, indicating a well-differentiated population and therefore distinct from the usual ductal hyperplasia, which expresses CK5/6. In addition, all forms of CCLs are strongly and diffusely positive for ER immunostaining (especially ER- $\alpha$ ) and PR, much more than seen in the normal epithelium. Increased expression of androgen receptor (AR) has also been reported (Schnitt 2003b). Proliferative Ki-67 indices are higher according to the progression from CCH to FEA, starting from less than 5% to higher levels in FEA.



**Fig. 7** Algorithmic approach to the diagnosis of columnar cell lesions and flat epithelial atypia





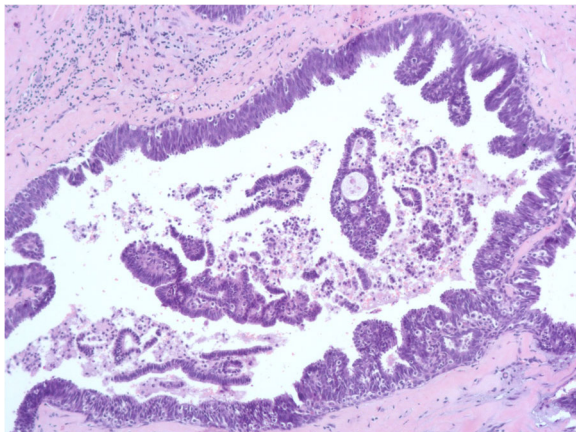
**Fig. 8** Atypical ductal hyperplasia: mild nuclei atypia with crowding and complex architecture

Although proliferation is very low in all CCLs, FEA is commonly positive for bcl-2, an anti-apoptotic proto-oncogene related protein, and cyclin D1, a cell cycle regulator (Dabbs 2012). The ER- $\alpha$ /ER- $\beta$  expression ratio increased during carcinogenesis, as did expression of cyclin D1 and bcl-2, leading to a conclusion that FEA, ADH and lobular neoplasia may represent a family of precursors leading to the development of the luminal A subclass of breast cancer (Schnitt 2003b) (Table 2).

At present, there are no prognostic or predictive factors for a progressive behavior of these cellular alterations (Dabbs 2012).

#### Genetic alterations in CCLs

In CCLs, chromosomal alterations are rare in lesions without atypia and more frequent when atypia is present. In FEA, genetic alterations are clonal, and it seems they are progressively accumulated from



**Fig. 9** Ductal carcinoma in situ: arch formation and complex architecture with real micropapillary formations

columnar cell lesions without atypia to the columnar cell hyperplasia with atypia. Besides, CCLs share some of the chromosome alterations observed in ADH or DCIS and even well-differentiated invasive carcinomas, present within the same sample or lesion (Simpson et al. 2005).

CCLs chromosomal alterations were evaluated by Simpson et al. (Simpson et al. 2005). The authors demonstrated, by comparative genomic hybridization (CGH), that FEA showed recurrent losses on 16q, 17p and X, and gains on 15q, 16p and 19p: alterations shared by low-grade in situ (DCIS) and invasive carcinoma of the same specimens.

In 17 of 22 cases of FEA, Monfair et al. (Monfair et al. 2000) found a loss of heterozygosity (LOH) at one or more of the eight loci evaluated in their study, specially 11q21–23.2, 16q23.1–24.2 and 3p14.2. Again, these genetic alterations were also identified in adjacent in situ or invasive carcinoma (Monfair et al. 2000).

Dabbs et al. (Dabbs et al. 2006) reported LOH at 9q, 10q, 17p and 17q in FEA, similarly to DCIS and invasive carcinoma. The study indicated that there was a low prevalence of molecular alterations, but they were found in very low levels in CCC, with increasing numbers of identical aberrations that were carried through CCH, ADH and tubular carcinoma, indicative of a molecular “kinship” between the precursors and invasive tubular carcinoma.

These results suggest that at least some columnar cell lesions, particularly those with atypia (i.e., flat epithelial atypia), may be or become neoplastic proliferations or even a non-obligate precursor of low-grade DCIS as well as a precursor to invasive carcinoma, particularly tubular carcinoma. Another possibility is that they are the representation of satellite manifestation of genetic changes that may result in well-differentiated carcinomas since they are commonly seen associated. Other findings, such as a progressive methylation level reported from CCL to DCIS and invasive carcinoma corroborates this (Park et al. 2011; Verschuur-Maes et al. 2012).

Although high-level gene amplification was not verified in CCLs, copy number gains were found in several known breast cancer-related genes, such as ER (ESR1), CCND1 (cyclin D1) and CDH1, in the same progressive pattern when compared to DCIS and invasive carcinomas of the same lesion (Verschuur-Maes et al. 2014). Since the copy number changes observed were more prevalent in DCIS and invasive carcinoma than in CCLs, the corresponding gene alterations may represent rather late-occurring events in low nuclear grade breast carcinogenesis (Verschuur-Maes et al. 2014). It is interesting that these genes are related to over-expressed protein levels in previous immunohistochemical studies (Verschuur-Maes et al. 2014).

Although the notion of an early set of genetic alterations in CCLs is important, it is not yet translated to

**Table 2** Immunohistochemical features in columnar cell changes (CCC)

Immunoexpression	Columnar cell change (CCC)	Flat epithelial atypia (FEA)
ER	homogeneous	homogeneous
PR	homogeneous	homogeneous
Ki-67	focally positive	focally positive
CK19	positive	positive
CK5/6	negative	negative
Bcl-2	positive	positive
Cyclin D1	focally positive	positive (5–50% cells)

ER estrogen receptor, PR progesterone receptor

clinical management. Unfortunately, there are still too few data on this subject, and the few available studies are characterized by a small number of patients.

### Reproducibility

Since the proper description and introduction of columnar cell lesion in the WHO book (Tavassoli et al. 2003), a few authors have investigated the reproducibility of CCLs morphological diagnosis among pathologists. This concept was reevaluated at the 4th edition of the WHO Classification of Breast Tumors (2012) in 2012, with a better description of diagnostic criteria (Abdel-Fatah et al. 2007). During this period, some authors attempted to evaluate the reproducibility of those entities by pathologists. Working with 14 pathology trainees, Haupt et al. (Haupt et al. 2010) reported a better agreement (kappa coefficient) after a proper tutorial as training for CCL diagnosis. Tan et al. (Tan et al. 2005) also reached the same improvement after a tutorial.

O'Malley et al. (O'Malley et al. 2006) described a nearly ideal agreement (91.8%, kappa = 0.83) on distinguishing FEA from CCLs without atypia when only breast pathologists evaluated the breast biopsies. More recently, Gomes et al. (Gomes et al. 2014) conducted a larger retrospective study with 153 cases previously diagnosed as CCL by a general pathologist which underwent consultant review by a breast pathology expert afterwards. The agreement between the original report and the later review was weak (kappa = 0.38 and 0.47 for FEA) in CCLs, suggesting that the vast majority of general pathologists require proper training for identifying CCLs, since diagnostic criteria were defined only in recent years.

### Clinical implications

A lot has been published concerning the clinical significance and suitable management of patients with CCLs in the last 15 years. CCLs has been increasingly diagnosed after 1980 with the adoption of screening mammography programs and the standardization and classification by Schnitt et al. in 2003 (Schnitt and

Vincent-Salomon 2003). As the descriptions and publications still lack uniform terminology, the exact clinical significance is still evolving. However, important key features noteworthy are that CCLs: 1) are multifocal, 2) are most common in perimenopausal women, 3) are frequently associated with microcalcifications, 4) are observed isolated in a biopsied breast lesion or coexisting with a progressive spectrum of atypical lesions in the same area, such as atypical ductal hyperplasia (ADH), lobular neoplasia (lobular hyperplasia and lobular carcinoma in situ), low-grade DCIS..

Within CCL's spectrum, FEA is the entity of greatest clinical concern and is usually the found with increasing frequency in breast biopsies in asymptomatic patients in which biopsy is indicated by the presence of microcalcifications (Schnitt 2003c).

### Significance of FEA in breast core biopsies concerning patient management

FEA was formally defined in a World Health Organization (WHO) book (Tavassoli et al. 2003) in 2003 as “presumably neoplastic intraductal alteration characterized by replacement of native epithelial cells with up to five layers of mildly atypical cells that have no architectural atypia.” This definition turned the range of lesions designated as FEA more strict and reproducible. The literature is controversial concerning what is the best management of patients with FEA solely (and without other atypical or neoplastic lesions diagnosed in breast biopsies) (Lakhani et al. 2012). Some research groups indicate the excision of the lesion and others have a more conservative approach, indicating mammographic follow-up assessments only. The current National Comprehensive Cancer Center (NCCN) guidelines (National Comprehensive Cancer Center 2017) suggest that FEA may not require surgical excision, although the identification of patients suitable for observation is unspecified. Recently, two large series and one meta-analysis contributed to putting together a recommendation that is defined in more details. Rudin et al. (Rudin et al. 2017) reviewed 250 studies from 2003 to 2015 regarding FEA and upgrading for ADH or cancer. After statistical adjustments of heterogeneity, 16 studies reporting FEA according to the WHO criteria showed a 7.5% upgrade for cancer (DCIS or invasive) and 18.6% for ADH. It is remarkable, though, that 10 papers reported that FEA patients who did not undergo excision had only a 2% cancer rate a few years later.

Looking specifically at the risk of breast cancer, Said et al. (Said et al. 2015) reported the outcome of 282 women with FEA with a longer follow up period (mean 17 years), with a final relative risk of subsequent breast cancer of only 2. Therefore, it seems we have different decisions to look at: the clinical approach of a patient with a breast lesion diagnosed with FEA by biopsy, and

the long-term management according to the relative risk of cancer. This apparent underestimation in FEA is in concordance to the concept previously described by Rosen (Rosen 1999a), and later confirmed in molecular biology level studies, that FEA is part of a triad comprehending ADH, FEA and tubular carcinoma (Said et al. 2015).

The understanding that FEA usually does not occur as an isolated lesion and may be associated to other entities sometimes more worrisome indicates that proper evaluation and description of such findings is important.

FEA is commonly seen adjacent to other columnar cell alterations, such as ductal hyperplasia with columnar features and columnar changes. It frequently resembles what Rosen has described as “the Rosen triad”, and more recently Abdel-Fatah et al. also described as the non-obligate triple negative pathway (Rosen 1999b; Abdel-Fatah et al. 2007; Sahoo and Recant 2005; Abdel-Fatah et al. 2008). This feature is also described by Said et al. (Said et al. 2015) with FEA associated to other proliferative lesions almost universally.

Therefore, it is always advisable to carefully look around a spotted FEA lesion to find potential proliferative lesions contained in a given breast specimen. Additional levels from the block or analysis of the whole sample available, by submission of the remainder specimen for histologic examination, is advisable to rule out the presence of ADH or DCIS foci (Schnitt 2018).

Concerning surgical management, it is generally considered that patients with only columnar cell changes or columnar cell hyperplasia, without atypia, should remain under conservative observation. Rudin et al. (Rudin et al. 2017) suggest a general recommendation to perform surgical excision for FEA found on core needle biopsy, which must be validated by literature. However, some recent studies with patients with FEA who had all microcalcifications removed and thoroughly sampled report that they may reach a lower risk of cancer, of 0–7% (Calhoun 2018; Chan et al. 2018; Schiaffino et al. 2018). The absence of other higher risk lesions or radiologic-pathologic concordance are conditions that indicate avoiding the surgical resection (Chan et al. 2018). Certainly, this issue will remain controversial until a better understanding of FEA is reached.

When FEA is reported together with other lesions, such as ADH or DCIS, it is more coherent to conduct clinical management as performed with other lesions. In excision specimens, the margins should also be considered positive if they bear DCIS or invasive carcinoma (Schnitt and Vincent-Salomon 2003).

## Conclusions

Among CCLs, FEA actually receives more attention due to atypia involved.

Intraductal proliferations with architectural complexities such as cribriform patterns, rigid cellular bridges, and true micropapillary pattern should not fall into the FEA category and are best classified as ADH or DCIS.

FEA has been considered a non-obligate pre-neoplastic lesion and progression of these lesions to invasive cancer has been reported as increasingly low (2–7%). This arises controversy to the management of those lesions, and further intervention is restricted to cases with other premalignant lesions (ADH, DCIS) or in radiology-pathology disagreement.

Proper training or tutorials are advisable for general pathologists in order to teach them how to identify CCLs with confidence.

## Acknowledgements

The authors thank Patricia Logullo for text reviewing.

## Funding

This study received no funding.

## Availability of data and materials

This is a literature review, with no reporting of original data.

## Authors' contributions

Both authors (AL and CN) contributed equally to the literature review, manuscript writing and final approval of the version to be published.

## Ethics approval and consent to participate

This is a literature review, without participation of human subjects or animals. Therefore, informed consent or ethical approval are waived.

## Consent for publication

This is a literature review, without participation of human subjects or animals. Therefore, informed consent or ethical approval are waived.

## Competing interests

The authors declare that they have no competing interests.

## Publisher's Note

Springer Nature remains neutral with regard to jurisdictional claims in published maps and institutional affiliations.

## Author details

<sup>1</sup>Escola Paulista de Medicina, Universidade Federal de São Paulo, São Paulo, Brazil Departamento de Patologia, Universidade Federal de São Paulo (UNIFESP), Rua Botucatu, 740, São Paulo, SP CEP 04023-062, Brazil. <sup>2</sup>Femme laboratories Rua desembargador Elizeu Guilherme, 200, São Paulo, Brazil. <sup>3</sup>Escola Paulista de Medicina, Universidade Federal de São Paulo, São Paulo, Brazil Departamento de Ginecologia, Disciplina de Mastologia, Universidade Federal de São Paulo (UNIFESP), Rua Botucatu, 740, São Paulo, SP CEP 04023-062, Brazil.

Received: 14 May 2018 Accepted: 11 September 2018

Published online: 15 January 2019

## References

- Abdel-Fatah TM, Powe DG, Hodi Z, Reis-Filho JS, Lee AH, Ellis IO (2008) Morphologic and molecular evolutionary pathways of low nuclear grade invasive breast cancers and their putative precursor lesions: further evidence to support the concept of low nuclear grade breast neoplasia family. *Am J Surg Pathol* 32(4):513–523. <https://doi.org/10.1097/PAS.0b013e318161d1a5> PubMed PMID: 18223478
- Abdel-Fatah TM, Powe DG, Hodi Z et al (2007) High frequency of coexistence of columnar cell lesions, lobular neoplasia, and low grade ductal carcinoma in



- situ with invasive tubular carcinoma and invasive lobular carcinoma. *Am J Surg Pathol* 31:417–426
- Azzopardi JG (1979) Problems in breast pathology. In: Major problems in pathology. Saunders, London
- Bloodgood JC (1906) Senile parenchymatous hypertrophy of female breast: its relation to cyst formation and carcinoma. *Surg Gynecol Obstet* 3:721–730
- Calhoun BC (2018) Core needle biopsy of the breast: an evaluation of contemporary data. *Surg Pathol Clin* 11:1–16
- Chan PMY, Chotai N, Lai ES, Sin PY, Chen J, Lu SQ et al (2018) Majority of flat epithelial atypia diagnosed on biopsy do not require surgical excision. *Breast* 37:13–17
- Cheatle GL (1920) Cysts, and primary cancer in cysts, of the breast. *Br J Surg* 8: 149–166
- Cheatle GL, Cutler M (1931) Tumours of the breast: their pathology, symptoms, diagnosis and treatment. Lippincott Company, Philadelphia
- Dabbs DJ (2012) Columnar cell alterations, flat epithelial atypia, and atypical ductal epithelial hyperplasia. Chapter 19. In: Breast pathology, 1st edn. Elsevier, p 349–350. eBook ISBN: 9780323245982, eBook ISBN: 9781455737567
- Dabbs DJ, Carter G, Fudge M, Peng Y, Swalsky P, Finkelstein S (2006) Molecular alterations in columnar cell lesions of the breast. *Mod Pathol* 19:344–349
- Fraser JL, Raza S, Chorny K, Connolly JL, Schnitt SJ (1998) Columnar alteration with prominent atypical snouts and secretions: a spectrum of changes frequently present in breast biopsies performed by microcalcifications. *Am J Surg Pathol* 22:1521–1527
- Gomes DS, Porto SS, Balabram D, Gobbi H (2014) Interobserver variability between general pathologists and a specialist in breast pathology in the diagnosis of lobular neoplasia, columnar cell lesions, atypical ductal hyperplasia and ductal carcinoma in situ of the breast. *Diagn Pathol* 9:121
- Haupt B, Schwartz MR, Xu Q, Ro JY (2010) Columnar cell lesion: a consensus study among pathology trainees. *Hum Pathol* 41:895–901
- Hicks DG, Lester SC (2016) Benign epithelial lesions: Columnar cell change, columnar cell hyperplasia, and flat epithelial atypia. In: Diagnostic pathology: breast, 2nd edn. Elsevier, section 5 p 100–103. eBook ISBN: 9780323442985 eBook ISBN: 9780323395267 Hardcover ISBN: 9780323377126 Imprint
- Lakhani SR, Ellis IO, Schnitt SJ, Tan PH, van de Vijver MJ (2012) In: WHO (ed) WHO Classification of Tumours of the Breast, Fourth edn
- McLaren B, Gobbi H, Schuyler PA, Olson SJ, Parl FF, Dupont WD et al (2005) Immunohistochemical expression of estrogen receptor in enlarged lobular units with columnar alteration in benign breast biopsies: a nested case-control study. *Am J Surg Pathol* 29:105–108
- Moinfar F (2009) Flat ductal intraepithelial neoplasia of the breast: a review of diagnostic criteria, differential diagnoses, molecular-genetic findings, and clinical relevance – it is time to appreciate the Azzopardi concept. *Arch Pathol Lab Med* 133:879–892
- Monfair F, Man YG, Bratthauer GL, Ratschek M, Tavassoli FA (2000) Genetic abnormalities in mammary ductal intraepithelial neoplasia-flat type (“clinging ductal carcinoma in situ”): a simulator of normal mammary epithelium. *Cancer* 88:2072–2081
- National Comprehensive Cancer Center. 2017 National Comprehensive Cancer Network Clinical Guidelines, Breast Cancer Risk Reduction. <https://www.nccn.org/about/news/ebulletin/ebulletindetail.aspx?ebulletinid=549>
- O'Malley FP, Mohsin SK, Badve S, Bose S, Collins LC, Ennis M et al (2006) Interobserver reproducibility in the diagnosis of flat epithelial atypia of the breast. *Mod Pathol* 19:172–179
- Oyama T, Maluf H, Koerner F (1999) Atypical cystic lobules: an early stage in the formation of low-grade ductal carcinoma in situ. *Virchows Arch* 435:413–421
- Park JK, Henry JC, Jiang J, Esau C, Gusev Y, Lerner MR et al (2011) miR-132 and miR-212 are increased in pancreatic cancer and target the retinoblastoma tumor suppressor. *Biochem Biophys Res Commun* 406:518–523
- Rosen PP (1999a) Columnar cell hyperplasia is associated with lobular carcinoma in situ and tubular carcinoma. *Am J Surg Pathol* 23:1561
- Rudin AV, Hoskin AL, Fahy A, Farrell AM, Nassar A, Ghosh K et al (2017) Flat epithelial atypia on core biopsy and upgrade to cancer: a systematic review and meta-analysis. *Ann Surg Oncol* 24:3549–3558
- Sahoo S, Recant WM (2005) Triad of columnar cell alteration, lobular carcinoma in situ, and tubular carcinoma of the breast. *Breast J* 11:140–142
- Said SM, Visscher DW, Nassar A, Frank RD, Vierkant RA, Frost MH et al (2015) Flat epithelial atypia and risk of breast cancer: a Mayo cohort study. *Cancer* 121: 1548–1555
- Schiaffino S, Gristina L, Villa A, Tosto S, Monetti F, Carli F et al (2018) Flat epithelial atypia: conservative management of patients without residual microcalcifications post-vacuum-assisted breast biopsy. *Br J Radiol* 91:1081
- Schnitt SJ (2003a) The diagnosis and management of pre-invasive breast disease: flat epithelial atypia – classification, pathologic features and clinical significance. *Breast Cancer Res* 5:263–268
- Schnitt SJ (2003b) Columnar cell lesions of the breast. *AJSP: reviews & reports* 8: 201–210
- Schnitt SJ (2018) Columnar cell lesions and flat epithelial atypia. In: Epstein JI, Schnitt SJ, Collins LC (eds) *Biopsy Interpretation of the Breast*, third edition. Wolters Kluwer, Philadelphia
- Schnitt SJ, Connolly JL, Tavassoli FA, Fechner RE, Kempson RL, Gelman R et al (1992) Interobserver reproducibility in the diagnosis of ductal proliferative breast lesions using standardized criteria. *Am J Surg Pathol* 16:1133–1143
- Schnitt SL, Vincent-Salomon A (2003) A columnar cell lesions of the breast. *Adv Anat Pathol* 10:113–124
- Simpson PT, Gale T, Reis-Filho J, Jones C, Parry S, Sloane JP et al (2005) Columnar cell lesions of the breast: the missing link in breast cancer progression? A morphological and molecular analysis. *Am J Surg Pathol* 29:734–746
- Tan PH, Ho BC, Selvarajan S, Yap WM, Hanby A (2005) Pathological diagnosis of columnar cell lesions of the breast: are there issues of reproducibility? *J Clin Pathol* 58:705–709
- Tavassoli FA, Hoeffler H, Rosai J, Holland R, Ellis IO (2003) Intraductal proliferative lesions. In: Tavassoli FA, Devilee P (eds) *Pathology & Genetics. Tumours of the Breast and Female Genital Organs*. World Health Organization Classification of Tumours. IARC Press, Lyon, pp 63–73 Available at: <https://www.iarc.fr/wp-content/uploads/2018/07/bb4-chap1.pdf>. Assessed in 2018 (Apr 20)
- Verschuur-Maes AH, de Bruin PC, van Diest PJ (2012) Epigenetic progression of columnar cell lesions of the breast to invasive breast cancer. *Breast Cancer Res Treat* 136:705–715
- Verschuur-Maes AH, Moelans CB, de Bruin PC, van Diest PJ (2014) Analysis of gene copy number alterations by multiplex ligation-dependent probe amplification in columnar cell lesions of the breast. *Cell Oncol (Dordr)* 37: 147–154
- Warren JC (1905) The surgeon and the pathologist. A plea for reciprocity as illustrated by the consideration of the classification and treatment of benign tumors of the breast. *Boston Med Surg J* 153:95–109
- Wellings SR, Jensen HM, Marcum RG (1975) An atlas of subgross pathology of the human breast with special reference to possible precancerous lesions. *J Natl Cancer Inst* 55:231–273

**Ready to submit your research? Choose BMC and benefit from:**

- fast, convenient online submission
- thorough peer review by experienced researchers in your field
- rapid publication on acceptance
- support for research data, including large and complex data types
- gold Open Access which fosters wider collaboration and increased citations
- maximum visibility for your research: over 100M website views per year

**At BMC, research is always in progress.**

Learn more [biomedcentral.com/submissions](https://biomedcentral.com/submissions)

