Lizardo-Thiebaud *et al.*
Surgical and Experimental Pathology (2023) 6:7
https://doi.org/10.1186/s42047-023-00132-2

Surgical and Experimental Pathology

CASE REPORT

Open Access

Re-thinking uterine fibroids in immunocompromised patients: adenomatoid tumors

Maria José Lizardo-Thiebaud[1], Guillermo Andrade-Orozco[1], Eduardo Cervantes-Álvarez[2,3], Sara Burbano-Rodríguez[1], Beatriz Sánchez-Hernández[1], Arnoldo Hernandez-Frausto[4], Oswaldo San Martín-Morante[1] and Arturo Ángeles-Ángeles[1,4*]

Abstract

Background Adenomatoid tumor (AT) is an ambiguous term used to describe benign mesothelial neoplasms, most often reported in organs of the reproductive system. Their neoplastic nature has been proven through the confirmation of pathogenic mutations in TRAF7. Several studies have proven an association between AToU and immunosuppression. Several groups have hypothesized immunosuppression causes an abnormal inflammatory state within mesothelial cells, increasing the likelihood of a selective activating mutations in TRAF7.

Case presentation A 34 year old female patient with a history of systemic lupus erythematosus was seen in the Emergency Department due to abdominal pain. A diagnosis of uterine leiomyomatosis was made and she was surgically intervened. Macroscopically, several intramural and subserosal uterine nodules were identified. On microscopic examination, all of them except one corresponded to adenomatoid tumours. A somatic mutation in TRAF7 was identified.

Conclusions Adenomatoid tumors have been associated with immunosuppression. A decrease in immunosurveillance may explain the association between adenomatoid tumours and immunosuppression. Confirming their neoplastic nature is crucial. Further studies are required to characterize the biological significance TRAF7 has in adenomatoid tumours and their association to immunocompromised states.

Keywords Adenomatoid tumor, Uterus, TRAF7, Immunosuppression

*Correspondence:
Arturo Ángeles-Ángeles
aaangeles2012@gmail.com
[1] Departamento de Anatomía Patológica, Instituto Nacional de Ciencias Médicas Y Nutrición Salvador Zubirán, Vasco de Quiroga, Mexico City, Mexico
[2] Department of Gastroenterology, Instituto Nacional de Ciencias Médicas Y Nutrición Salvador Zubirán, Vasco de Quiroga, Mexico City, Mexico
[3] Facultad de Medicina, PECEM, Universidad Nacional Autónoma de México, Mexico City, Mexico
[4] Present Address: Department of Imagenology, Instituto Nacional de Ciencias Médicas Y Nutrición Salvador Zubirán, Vasco de Quiroga, Mexico City, Mexico

Background

Adenomatoid tumor (AT) is an ambiguous term used to describe benign mesothelial neoplasms found mainly in organs of the reproductive system. Any organ covered by mesothelium may develop it, as it has also been described in pleura, peritoneum, pericardium and adrenal glands (Chen et al. 2017). In women, it commonly involves the fallopian tubes and the uterus (Chen et al. 2017; Hafiz et al. 2021; Quick and Solomon 2021).

The term was coined by Golden and Ash in 1945, a term they considered neutral and thus correctly described a tumor of unknown origin. It was regarded as a neoplasm

of lymphatic vessels (lymphangioma), a mixed tumor of lymphatic vessels and smooth muscle cells (leiomyoma and lymphangioma), a benign tumor of gland-like structures (adenoma) and even a low-grade adenocarcinoma (Hafiz et al. 2021).

With the help of electron microscopy and immunohistochemistry, the origin of the tumour was identified as being from mesothelial cells. ATs express mesothelial antigens (cytokeratin, calretinin) and lack endothelial antigens (factor VIII, Ulex europaeus I-lectin, CD34, CD31) (Hafiz et al. 2021; Quick and Solomon 2021; Stephenson and Mills 1986; Karpathiou et al. 2020; Contreras et al. 2009; Kawamura et al. 2000). Their neoplastic nature was confirmed with the finding of specific mutations in a gene member of the TNF receptor-associated factors, TRAF7 (Karpathiou et al. 2020; Itami et al. 2021; Zhu et al. 2018).

Adenomatoid tumors of the uterus (AToU) tend to occur in women of reproductive age. The detection rate in hysterectomy specimens is of 1–5% (Quick and Solomon 2021; Karpathiou et al. 2020). They are usually asymptomatic; however, they may be associated with vaginal bleeding, menorrhagia, and abdominal masses. In hysterectomy specimens, they are incidental findings, usually associated with other lesions of the genital tract, including, leiomyomas, adenomyosis, endometrial and ovarian cancer. Imaging features are non-specific. AToU are often misdiagnosed as leiomyomas (Hong et al. 2009; Mitsumori et al. 2000; Wakita et al. 2020). Most of the cases reported in the literature describe AToU with a cystic component, which may render them more conspicuous (Yorita et al. 2016; Kim et al. 2000; Manucha et al. 2015; Harada et al. 2012). Nevertheless, MRI may be helpful in the differential diagnosis (Meng et al. 2015).

Macroscopically, most AToU are solitary, well circumscribed lesions of small size located within the walls of the uterus. They are usually subserosal, found at the fundus and cornual region (Tiltman 1980; Quigley and Hart 1981). Multiple tumors are rare, with a frequency that ranges from 2.8 to 20% of cases (Quick and Solomon 2021; Nakayama et al. 2013; Young and Taylor 1967). Large lesions usually harbor a cystic component (Bisset et al. 1988; Nogales et al. 2001; Rosa et al. 1992). The cut surface appears firm, homogeneous, with a white to tan color and a whorled appearance. Histologically they are composed of solid, tubular, cord-like, nested, microcystic, trabecular or spindled cell morphology. The glandular cavities are composed of flat, cuboidal, or columnar cells with abundant, acidophilic or lightly stained cytoplasm (Chen et al. 2017; Quick and Solomon 2021; Karpathiou et al. 2020).

A recent finding is the association of AToU and immunosuppression. Though previous articles had reported ATs in immunosuppressed patients, none demonstrated a clear association, and they considered ATs fortuitous findings (Angeles-Angeles et al. 1997). The changing prevalence of immunocompromised states might explain the growing interest in proving the association. Several groups have hypothesized immunosuppression causes an abnormal inflammatory state within mesothelial cells, increasing the likelihood of selective activating mutations in TRAF7 (Itami et al. 2021; Goode et al. 2018).

We present here a case of a female patient with a history of immunosuppression who underwent a simple hysterectomy as a treatment for uterine leiomyomas. Pathological examination revealed multiple ATs, confirmed through immunohistochemistry and molecular pathology.

Case presentation

A 34 year old female patient with a history of systemic lupus erythematosus (diagnosed in 2011), lupus valvulitis and chronic kidney disease (KDIGO V), was seen in the Emergency Department due to an intermittent, periumbilical abdominal pain with irradiation to the pubis. At the time, she was receiving prednisolone, nebivolol, amlodipine, folic acid, calcitriol, and erythropoietin. A transvaginal ultrasound was made, which reported uterine nodules. Blood tests showed a beta-hCG of 5.41 mUI/mL. After administration of an anticholinergic (butylscopolamine), she was scheduled for a gynecological evaluation. She reported a regular cycle, with episodes of menorrhagia and dysmenorrhea, which had decreased after a recent dose of medroxyprogesterone. Her complete blood count showed a hemoglobin of 9.1 g/dl and a hematocrit of 27.3%. The CT scan showed several tumors within the anterior and posterior wall, the largest measuring 5×5 cm and 4×4.2 cm respectively. Both tumors had grown when compared to a pelvic ultrasound and CT scan (Fig. 1). The MRI showed similar characteristics. CA 125 levels were within range (15.4 IU/ml). The patient underwent a simple hysterectomy with minimal bleeding (50 ml). On follow-up, the patient has had an optimal evolution.

On macroscopic evaluation, the uterus was of 4×5x6 cm and 140 gr of weight, with an irregular contour, and a homogenous pink hue (Fig. 2). Three subserosal tumors were identified, one in the anterior wall (1 cm in diameter) and two in the posterior wall (largest one, of 4.5 cm in diameter, smaller one 8 mm in diameter), as well as several intramural at the corpus, the largest of 2 cm in diameter. On cut-section, the uterine cavity measured 8×3 mm, the uterine wall measured 2 cm in its thickest dimension. The tumors were well-circumscribed, non-encapsulated, with a solid homogeneous cut-surface, a

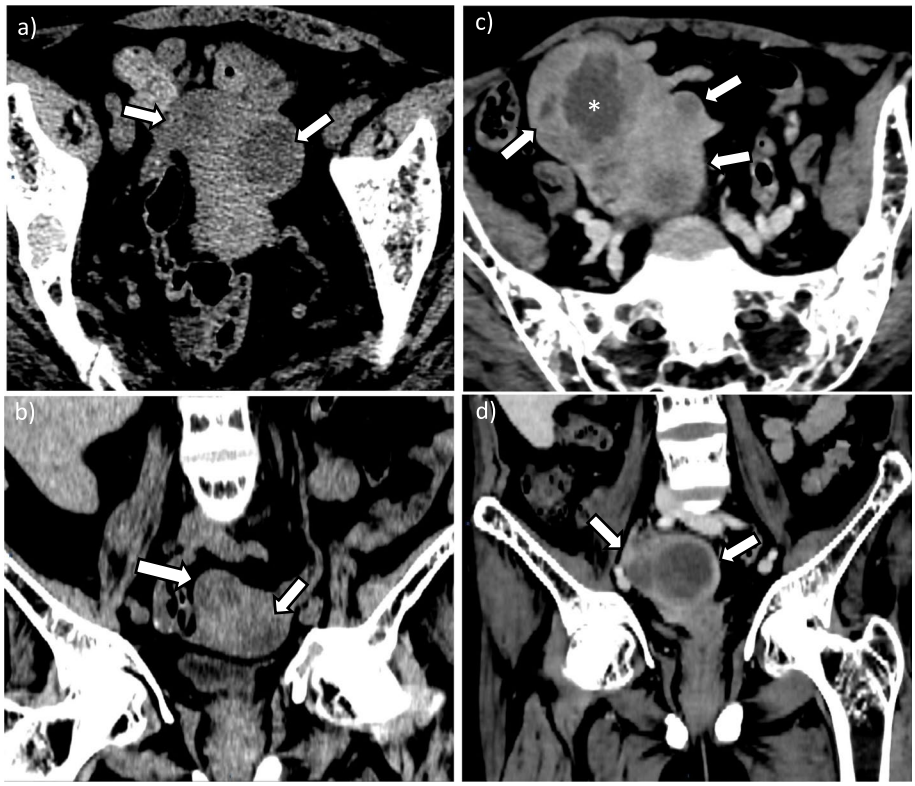

Fig. 1 Radiological findings: **a**-**b** A abdomino-pelvic CT scan taken 4 years before, evidenced three ovoid, hypodense uterine masses (two shown here, white arrows), with ill-defined borders, the largest measuring 2.5 × 1.9 cm (without contrast; axial and coronal sections). **c**-**d** The recent abdominopelvic CT scan showed an increase in the size and number of the uterine masses, the largest measuring 5 × 5 cm; some with a hypodense center suggesting necrosis (asterisk) (venous phase; axial and coronal sections)

light brown hue and a rubbery appearance. No necrosis was identified.

On microscopic examination, three of the tumors had a mixture of slit-like and tubular structures, alternating with smooth muscle fibers (Fig. 3). The pseudovascular channels were lined by a flat epithelium, with a bland cytology. Immunohistochemistry analysis for mesothelial antigens were positive (Fig. 3). A submucosal leiomyoma was also identified.

Furthermore, mutations in the WD40 repeat region of TRAF7 gene were sought using Sanger sequencing (see Supplementary material & methods) (Itami et al. 2021). A somatic point mutation was identified in exon 18, c.1681A > C (Fig. 4). As described in the literature, the mutation peak is low, but it was identified in repeated assays (Goode et al. 2018; Tamura et al. 2018).

Discussion and conclusions

An exhaustive review of the literature was done to identify the characteristics of AToU in patients with history of immunosuppression. Search was done specifically for case reports and case series adenomatoid tumors in the uterus, using the following key terms: "multiple", "diffuse" and "adenomatoid tumor of uterus", using databases such as PUBMED and Scielo, including only indexed journals with articles written in English, Spanish, French and German.

The terms multiple and diffuse were used interchangeably in most of the literature found and thus were both considered key terms. Immunosuppression was not considered as a key term as few reports and series describe to detail the clinical history. Cases with multifocal lesions and solitary tumors were excluded, as multifocal cases considered AT in uterus, ovary, Fallopian tubes and fimbria. Cases without mention of the number of lesions were considered solitary tumors and therefore excluded. Twenty-two articles were retrieved from a total of 103, between the years 1950 and 2021 (Table 1). From these articles, 35 cases of multiple AToU were identified (Chen et al. 2017; Hafiz et al. 2021; Konishi et al. 1984; Kalidindi and Odejinmi 2010; Tiltman 1980; Nakayama et al. 2013; Young and Taylor 1967; Nogales et al. 2001; Goode et al. 2018; Tamura et al. 2018; Lerias et al. 2021; Ranjan et al.

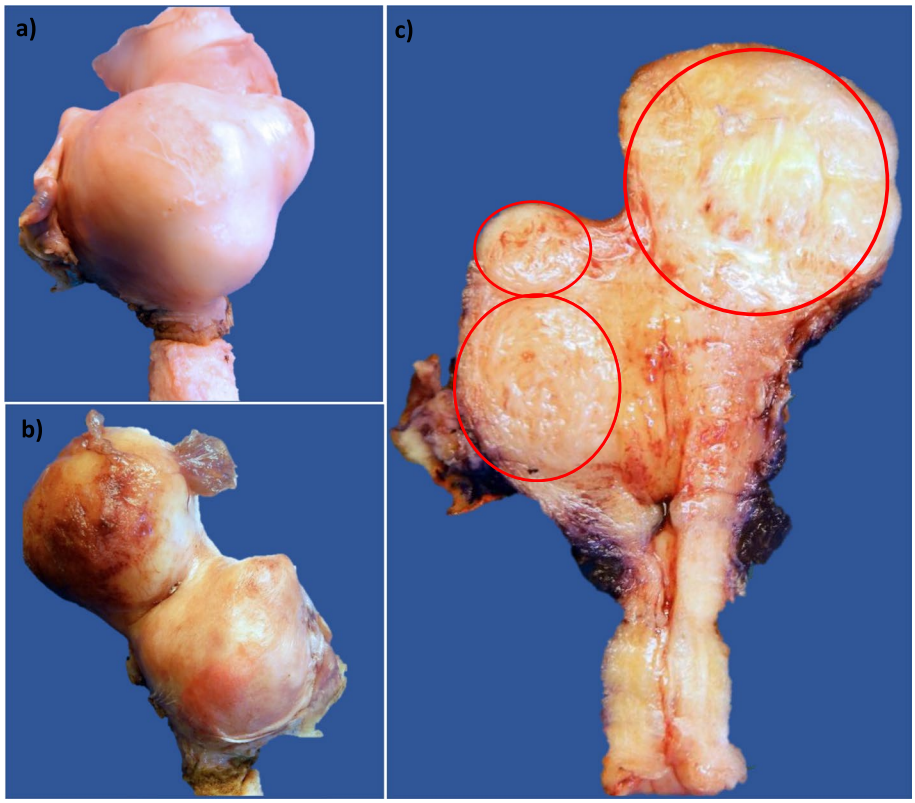

Fig. 2 On macroscopic examination, **a**) the uterus is deformed by several tumors located in the anterior and posterior walls. **b** The posterior surface shows papillary projections on the serosal surface covering the tumor. **c** Upon section, there are three solid tumors within the myometrium, the largest showing a nodular surface, each of the nodules with a yellowish whorled appearance, similar to the rest of the tumors within the corpus

2015; Duval et al. 2008; Saran et al. 2007; Amre et al. 2005; Cserni et al. 2003; Chee et al. 2003; Bulent Tiras et al. 2000; Livingston et al. 1992; Srigley and Colgan 1988; Luchs et al. 2000; Stefano et al. 1998). The clinical elements found in common are also shared with the case presented above.

The case series and case reports included women from age 25 to 60 years, with a mean of 41. Abnormalities in menstrual bleeding occurred in 62% of the cases (20 out of 32), which was considered the main reason for the surgical treatment. Most of them had a pre-surgical diagnosis of fibroids or a uterine mass compatible with uterine fibroids. Hysterectomy was the most frequent surgical procedure (24 out of 35 cases), with the rest undergoing enucleation. Secondary immunodeficiency due to immunosuppressive treatment for autoimmune diseases or solid organ transplantation was identified in 12 cases (37.5%) (Hafiz et al. 2021; Goode et al. 2018; Tamura et al. 2018; Lerias et al. 2021; Duval et al. 2008; Cserni et al. 2003; Chee et al. 2003; Bulent Tiras et al. 2000; Livingston et al. 1992). The rest had either no history of immunosuppressive treatment or no clinical information of the sort was provided.

In the cases where the number of tumors was reported, the average number calculated was of 3 tumors. The average size of each was of 3.77 cm, considering the largest size reported in the revised articles (diameter). The location of the tumors varied; however, an intramural location was the most frequent location (10 out of 35 cases), though our case presented intramural and subserosal. The histological pattern that predominated varied as well: about a third (10 out of 35) presented mixed patterns of which the combination of adenoid and angiomatoid patterns were the most frequent. Likewise, the second most frequent pattern was the cystic pattern alone (7 out of 35 cases). Cases with only adenomatoid, angiomatoid or solid patterns were less frequent. Immunohistochemistry assays were used in most of the cases. The preferred biomarker being pan-cytokeratin. Other markers used were D2-40, high molecular weight cytokeratins and calretinin. All the cases combined mesothelial antigens with endothelial antigens for differential diagnosis.

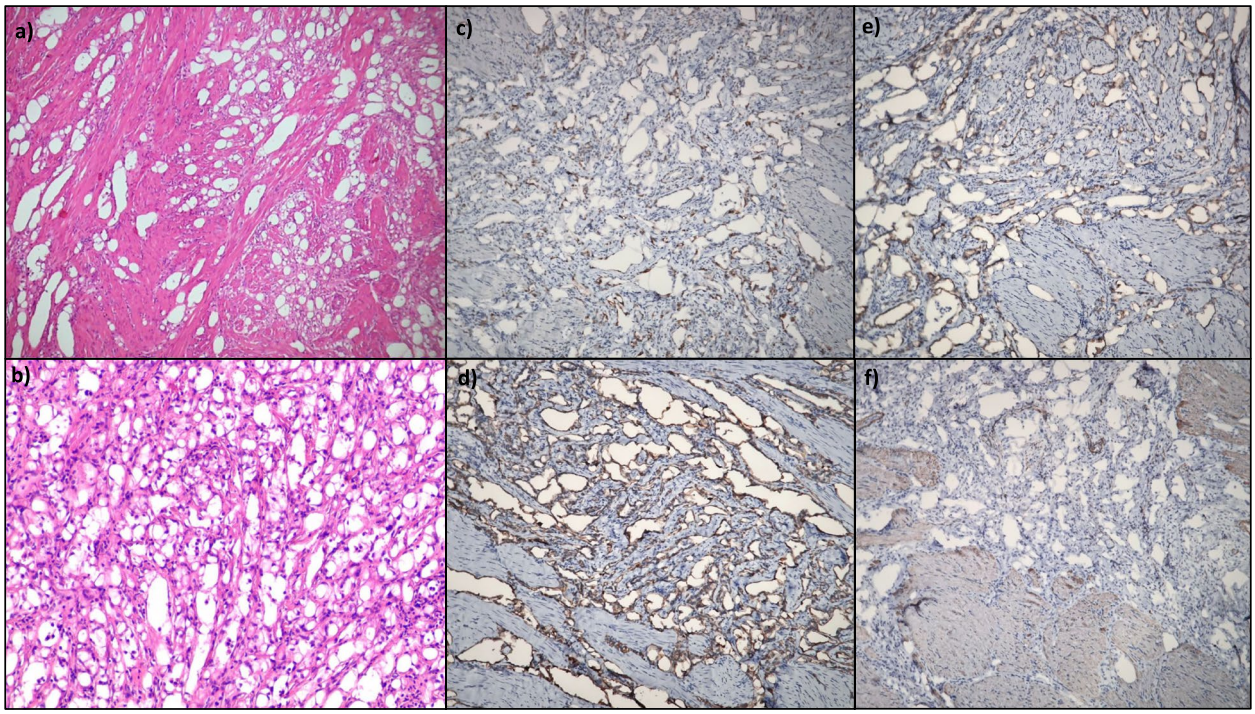

Fig. 3 On microscopic examination of the largest lesion, **a** the adenomatoid tumor is composed of infiltrating pseudovascular channels that alternate with smooth muscle fibers (H&E, 10x). **b** Some areas showed a mixture of pseudovascular channels, which were lined by a flat epithelia and had an empty lumen, and cords of cells with abundant, vacuolated cytoplasm and oval nuclei (H&E, 20x). The immunohistochemistry assay showed positivity for **c**) calretinin, **d**) CK and **e**) D2-40, and **f**) negativity to actin (10x)

A characteristic of AToU is their morphological heterogeneity (Contreras et al. 2009; Quigley and Hart 1981; Canedo-Patzi et al. 2006). Morphological classifications have been proposed but none have been unified. In 1950, Lee et al. described three patterns: a) a plexiform pattern, which contains mostly cords of cuboidal cells; b) a canalicular pattern, which consists of slit-like structures lined by flat cells and c) a tubular pattern, which are lined by cuboidal cells (Tiltman 1980). Several years later, Quigley and Hart described four types: a) the adenoid type, which presented gland-like structures; b) the angiomatoid type, characterized by pseudovascular channels; c) the cystic type with large cavities replacing most of the tumor and d) the solid type, with cells arranged in cords and nests (Quigley and Hart 1981).

Parallel to our case, most of the cases revised presented two patterns of growth, the tubulo-canalicular or angiomatoid-adenoid patterns being the most frequent combinations. In their study, Quigley and Hart found these patterns did not correlate with the age of the patient, the phase of the endometrium, nor the size of the neoplasm. In the same line, our review showed that the microscopic pattern does not correlate with the clinical presentation nor the macroscopical characteristics, specifically the focality and number of ATs.

Interestingly, since first described, AToU are asymptomatic. However, most of the reports where ATs are incidental findings describe a single tumor. Considering our case and our review of multiple AToU, bleeding is a common sign, which may be related to number and size of the tumors.

We found immunosuppression in 13 cases of multiple AoT. The frequency of immunosuppression reported in the literature varies from 25 to 58%, which coincides with the calculated frequency within a population of multiple AToU (Karpathiou et al. 2020; Tamura et al. 2018; Mizutani et al. 2016). Considering the frequency of immunosuppression in multiple AToU (37%) to the overall frequency of multiple AToU (35 out of 242 cases, 14.46%), the immunological state does not seem to determine the number of lesions. Only a third of the multiple AToUs were associated with immunosuppression. One would expect an association of immunocompromise to all 14.46% cases revised (35 out of 242). Nevertheless, a reporting and a sampling bias must be considered. Taking this into consideration, identifying clonality in AToU becomes

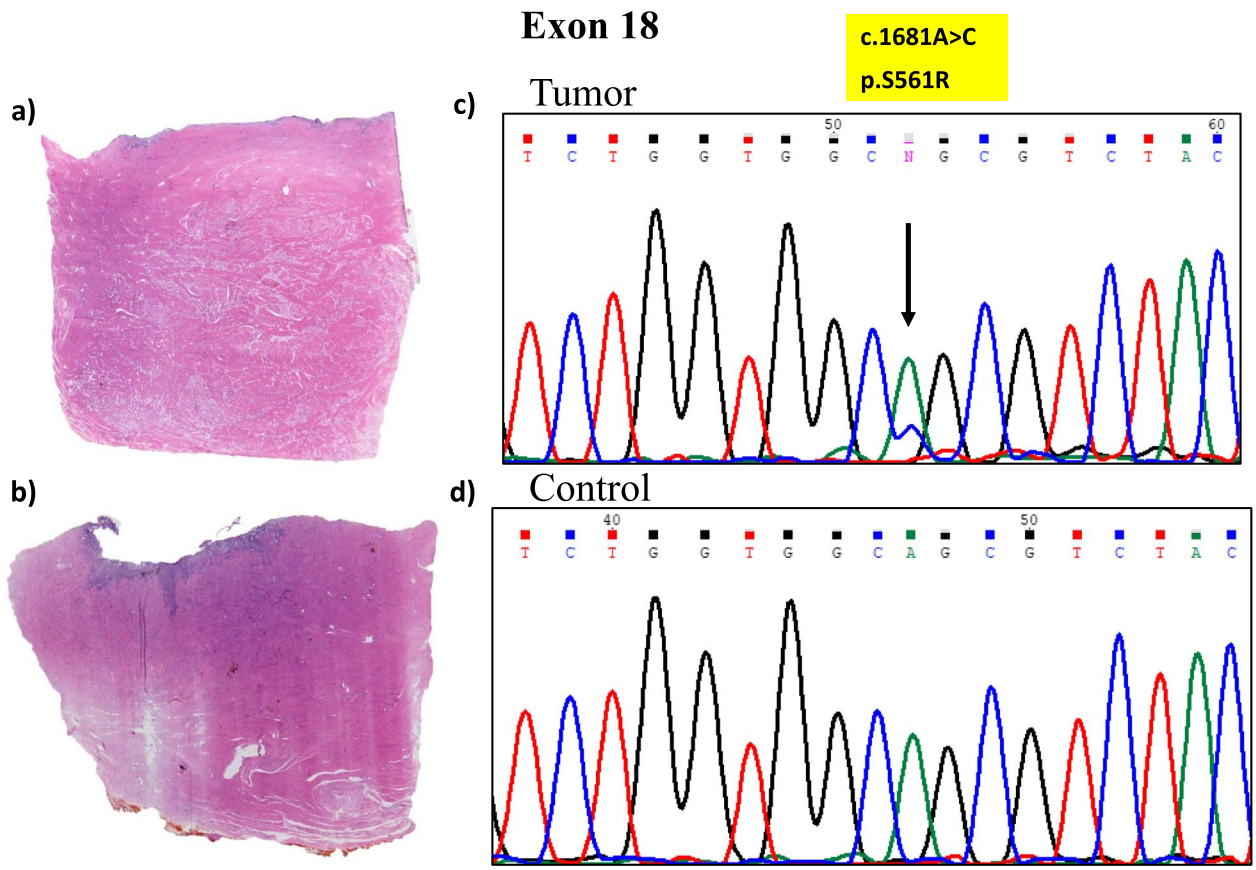

Fig. 4 Electropherogram representation of the Sanger sequencing of mutation S561R: **a**-**b**) histological sections of the tumor (largest in size) and normal tissue from where DNA was extracted; **c**-**d**) show the DNA electropherogram of exon 18 where a single nucleotide mutation was identified (c.1681A > C)

significant as it elucidates the neoplastic nature of the tumor. We sought mutations in TRAF7, which have been reported specifically in the WD-40 repeat region (Itami et al. 2021).

TRAF7 is a gene encoding a protein belonging to the family of TNF receptor-associated factors. Unlike the rest of the members of the TRAF family, it lacks a TRAF-C (also known as MATH) homology domain, having instead a WD40 repeat domain (Zhu et al. 2018). The TRAF domain is located at the C-terminus and contains a TRAF-N coiled-coil domain and a conserved TRAF-C domain (Soni et al. 2007). It allows protein–protein interactions with factors like NF-κB, MAPKs and IRFs (Zapata et al. 2007). Though TRAF7 lacks the MATH domain, the remaining TRAF-N seems sufficient for protein–protein interaction. There is data showing TRAF7 promotes ubiquitination and allows activation of NF-κB (Goode et al. 2018; Zotti et al. 2011). Mutations identified in ATs are mostly missense mutations and occur more frequently in the WD40 repeats region of the protein, in six specific amino acids, including S561R. These mutations are thus considered hotspots (Zhu et al. 2018). The mutation identified (c.1681A > C) has not been previously described in the literature nor in databases, including 1000G nor gnomAD (Goode et al. 2018; Tamura et al. 2018).

Considering the published data thus far, further studies are needed to characterize mutations in TRAF7, determine their significance in the development of AToU and identify promoters, not only in immunosuppressed patients but also in the general population. Indeed, adenomatoid tumors found in immunosuppressed patients could be another example of the role our immune system plays in clonal evolution.

Conclusion

Adenomatoid tumours of the uterus are infrequent. They are usually asymptomatic but are associated with other pathologies of the uterus. Most are incidental findings

Table 1 Articles presenting cases of multiple adenomatoid tumors of the uterus

Year	Authors	Age	Gynecological antecedents	Commorbidities	Immunodeficiency	AUB	Type of treatment	Number	Size (largest diameter; cm)	Location	Histopathological variant	Positive IHC markers	Negative IHC markers
2022	case	34	pain	SLE, CKD	yes	yes	hysterectomy	4	4.5	SS, IM	adenoid + angiomatoid	CK, CR, D2-40	actin
2021	Hafiz B et al.	35	pain	no data	no	yes	enucleation	multiple	9	unknown	adenoid	D2-40, CK7	CD31, CK20
2021	Lerias S et al.	4 out of 6		ESRD	2 out of 6								
		median 45	no data	no data		yes	hysterectomy	multiple		IM	cystic + angiomatoid	no data	no data
		median 45	no data	no data		yes	hysterectomy	multiple	4.5	IM	cystic + angiomatoid	no data	no data
		median 45	no data	no data		yes	hysterectomy	multiple	3	SM	cystic + angiomatoid	no data	no data
		median 45	no data	no data		yes	hysterectomy	multiple	1.5	IM, SS	cystic + angiomatoid	no data	no data
2018	Goode et al.	1 out of 15											
		60	AToU	IHD;SOT	yes	no	hysterectomy	3	6	IM	no data	no data	no data
2018	Tamura et al.	6 out of 14											
		46	endometrial cancer	cytotoxic treatment	no	no	hysterectomy	multiple	50mm2	no data	no data	CK, D2-40, p16	no data
		39	endometrial cancer	cytotoxic treatment	no	no	hysterectomy	multiple	473mm2	no data	no data	CK, D2-40, p16	no data
		38	endometrial cancer	SLE	yes	no	hysterectomy	multiple	90mm2	no data	no data	CK, D2-40, p16	no data
		41	leiomyoma	SOT	yes	no	hysterectomy	multiple	85mm2	no data	no data	CK, D2-40, p16	no data
		44	leiomyoma	SLE	yes	no	hysterectomy	multiple	550 mm2	no data	angiomatoid	CK, D2-40, p16	no data
		55	none	MAGIC syndrome	yes	no	hysterectomy	multiple	10mm2	no data	no data	CK, D2-40, p16	no data
2017	Chen HF et al.	4 out of 102											
		mean 39.3	menstrual disorder	no data	no data	yes	n/a	multiple	average 2.3	IM, SS	adenoid + angiomatoid	HBME-1, CR, D2-40 CK	CEA

Table 1 (continued)

Year	Authors	Age	Gynecological antecedents	Commorbidities	Immunodeficiency	AUB	Type of treatment	Number	Size (largest diameter; cm)	Location	Histopathological variant	Positive IHC markers	Negative IHC markers
2014	Nakayama H et al.	1 out of 10											
		36	no data	no data	no	no data	enucleation	2	1	no data	no data	no data	no data
2015	Ranjan et al.	1 out of 5											
		36	menstrual disorder	no data	no	yes	hysterectomy	mutliple	3	IM	cystic	no data	no data
2010	Kalidindi & Odejinmi	1out of 2											
		39	infertility	none	no	yes	enucleation	2	7	IM	adenoid + angiomatoid	CAM5.2	no data
2008	Duval H et al.	43	leiomyoma	SOT	yes	yes	hysterectomy	3	3	IM	adenoid	AE1/AE3, CR, HMBE1	no data
2007	Saran M et al.	34	infertility	none	no	yes	enucleation	2	10	SS	cystic	CR, CK5/6	CD31, CD34, BerEP4, CEA
2005	Amre R et al.	52	menstrual disorder	degenerative diseases	no	yes	hysterectomy	3	1.5	SS,IM	solid	AE1/AE3	no data
2003	Cserni G et al.	41	menstrual disorder	IgA nephropathy	yes	yes	hysterectomy	diffuse	2	IM	adenoid + angiomatoid	CK	no data
2003	Cheng & Wee	34	painless abdominal mass	IgA nephropathy, SOT	yes	yes	hysterectomy	diffuse	3	IM	adenoid + angiomatoid	AE1/3, HBME-1, CR, focal thrombomodulin, vimentin	CD34
2001	Nogales FF et al.	1 out of 50											
		mean 45	menstrual disorder	no data	no data	yes	hysterectomy	2	2.1	SS	adenoid + angiomatoid	CAM5.2, CR, HMBE1	ER; PR, EMA, inhibin
2000	Luchs J et al.	25	menstrual disorder	no data	no data	yes	hysterectomy	multiple		IM	no data	no data	no data
2000	Bülent Tiras et al.	34	menstrual disorder	chronic glomerulonephritis; SOT	yes	yes	enucleation	8	5	IM, SS	cystic	CK	factor VIII
1998	Di Stefano et al.	30	menstrual disorder	none	no data	yes	enucleation	3	4.5	IM	adenoid + angiomatoid	HMBE1,CK; focal EMA, vimetin	Ber-EP4, factor VIII, CEA, CD15

Table 1 (continued)

Year	Authors	Age	Gynecological antecedents	Commorbidities	Immunodeficiency	AUB	Type of treatment	Number	Size (largest diameter; cm)	Location	Histopathological variant	Positive IHC markers	Negative IHC markers
1992	Livingston et al.	39	menstrual disorder	SLE, SOT	yes	yes	hysterectomy	3	4	SS	cystic	CK	factor VIII
1988	Srigley & Colgan	45	menstrual disorder	HTN	no	yes	hysterectomy	multiple	3	IM, SS, SM	angiomatoid + cystic	CK	factor VIII, EMA
1984	Konishi & Fujii	39	menstrual disorder	none	no	yes	hysterectomy	multiple	no data	IM	adenoid	no data	no data
1980	Tiltman AJ	2 of 12											
		47	menstrual disorder	no data	no data	no data	hysterectomy	2	3	IM, SS	adenoid	no data	no data
		47	menstrual disorder	no data	no data	no data	hysterectomy	2	0.8	IM, SS	adenoid	no data	no data
1967	Young & Taylor	1 of 14											
		median 42	none	no data	no data	no	hysterectomy	2	0.7–7.5 cm	SS	adenoid + angiomatoid	no data	no data

AUB abnormal uterine bleeding, *IHC* immunohsitochemistry, *ESRD* end-stage renal disease, *IM* intramural, *SS* subserosal, *SM* submucosal, *AToU* adenomatoid tumor of the uterus, *IHD* ischemic heart disease, *SOT* solid organ transplantation, *SLE* systemic lupus erythematosus, *CR* calretinin, *HTN* hypertension

and are frequently misdiagnosed as uterine fibroids. Multiplicity is also infrequent but tends to be more common in patients with immunodeficiency. They present microscopically with a mixed pattern of growth. Mutations in the WD40 region of the gene TRAF7 confirm their neoplastic nature. Our case includes a mutation not previously described in AToU, TRAF7 c.1681A > C.

Abbreviations

AT	Adenomatoid tumour
AToU	Adenomatoid tumors of the uterus
MRI	Magnetic resonance imaging
TRAF7	TNF receptor-associated factors 7

Supplementary Information

The online version contains supplementary material available at https://doi.org/10.1186/s42047-023-00132-2.

Additional file 1.

Acknowledgements
Not applicable.

Authors' contributions
GAO, MJLT, ECA, SBR and AAA all contributed equally to the case and writing of the manuscript. AHF contributed with the case. BSH contributed with the results on genetic testing. The author(s) read and approved the final manuscript

Funding
Not applicable.

Availability of data and materials
All data generated or analyzed during this study are included in this published article [and its supplementary information files].

Declarations

Ethics approval and consent to participate
Not applicable.

Consent for publication
Written informed consent for publication of their clinical details and/or clinical images was obtained from the patient. A copy of the consent form is available for review by the Editor of this journal.

Competing interests
The authors declare that they have no competing interests.

Received: 20 January 2023 Accepted: 9 May 2023
Published online: 10 June 2023

References

Amre R, Constantino J, Lu S, Charney D, Luke's-Roosevelt S. Pathologic quiz case a 52-year-old woman with a uterine mass. Arch Pathol Lab Med. 2005;129:e77-8.
Angeles-Angeles A, Reyes E, Mufioz-Ferfiandez L, Angritt P. Adenomatoid tumor of the right adrenal gland in a patient with AIDS. Endocr Pathol. 1997;8(1):9.
Bisset D, Morris J, Fox H. Giant cystic adenomatoid tumour (mesothelioma) of the uterus. Histopathology. 1988;12(5):555–8.
Bulent Tiras M, Noyan V, Suer O, Bali M, Edali N, Yildirim M. Adenomatoid tumor of the uterus in a patient with chronic renal failure. Euro J Obstet Gynecol Reprod Biol. 2000;92:205–7. Available from: www.elsevier.com/locate/ejogrb.
Canedo-Patzi A, León-Bojorge B, Ortíz-Hidalgo C. Tumor adenomatoide del aparato genital. Estudio clinico- patológico e inmunohistoquímico de 9 casos. Gac Med Mex. 2006;142(1):59–66.
Chee L, Cheng MBBS, Wee A, Path MRC. Diffuse uterine adenomatoid tumor in an immunosuppressed renal transplant recipient. Int J Gynecol Pathol. 2003;22:198–201.
Chen HF, Liu XL, Liu AZ, Shi JS, Cui Y, Gao P. Uterine adenomatoid tumor: a clinicopathologic study of 102 cases. Int J Exp Pathol. 2017;10(9):9627–32.
Contreras L, Plass I, Ricci P. Tumores adenomatoides uterinos: estudio anatomo-patológico e inmunohistoquímico de 32 casos. Rev Chil Osbtet Ginecol. 2009;74(6):372–8.
Cserni G, Kocsis L, Pusztai Z, Godó G. Endometrial adenocarcinoma with coexisting adenomatoid tumor of the uterus. Gynecol Oncol. 2003;90(1):207–10.
de Rosa G, Boscaino A, Terracciano LM, Giordano G. Giant adenomatoid tumors of the uterus. Int J Gynecol Pathol. 1992;11:156–60.
Duval H, Rioux-Leclercq N, Bauville E, al Jaradi M, Burtin F. Tumeur adénomatoïde multinodulaire de l'utérus chez une patiente avec allogreffe rénale. Ann Pathol. 2008;28(4):308–10.
Di Stefano, Faticanti Scucchi R, Covello A, Martinazzoli C, Meli C, Bosman DL, Stefano Domenica D. Uterine diffuse adenomatoid tumor does it represent a different biological entity? Gynecol Obstet Invest. 1998;46:68–72. Available from: http://BioMedNet.com/karger.
Goode B, Joseph NM, Stevers M, van Ziffle J, Onodera C, Talevich E, et al. Adenomatoid tumors of the male and female genital tract are defined by TRAF7 mutations that drive aberrant NF-kB pathway activation. Mod Pathol. 2018;31(4):660–73.
Hafiz B, Silimi MH, Felmban W. Leiomyoadenomatoid tumors of the uterus: a case report and literature review. Am J Case Rep. 2021;22(1):e934012.
Harada N, Nobuhara I, Haruta N, Kajimoto M. Giant cystic adenomatoid tumour of the uterus. J Obstet Gynaecol (lahore). 2012;32(4):407–8.
Hong R, Choi DY, Choi SJ, Lim SC. Case report multicentric infarcted leiomyoadenomatoid tumor: a case report. Int J Clin Exp Pathol. 2009;2:99–103. Available from: www.ijcep.com/IJCEP801004.
Itami H, Fujii T, Nakai T, Takeda M, Kishi Y, Taniguchi F, et al. TRAF7 mutations and immunohistochemical study of uterine adenomatoid tumor compared with malignant mesothelioma. Hum Pathol. 2021;1(111):59–66.
Kalidindi M, Odejinmi F. Laparoscopic excision of uterine adenomatoid tumour: two cases and literature review. Arch Gynecol Obstet. 2010;281(2):311–5.
Karpathiou G, Hiroshima K, Peoc'h M. Adenomatoid tumor: a review of pathology with focus on unusual presentations and sites, histogenesis, differential diagnosis, and molecular and clinical aspects with a historic overview of its description. Adv Anat Pathol. 2020;27:394–407. Available from: http://journals.lww.com/anatomicpathology.
Kawamura K, Sekiguchi K, Shibata S, Fukuda J, Kodama H, Tanaka T. Immunohistochemical analysis of adenomatoid tumor of the uterus utilizing of monoclonal antibody HBME-1. Acta Obstet Gynecol Scand. 2000;79(9):798–9.
Kim JY, Jung KJ, Sung NK, Chung DS, Kim OD, Park S. Cystic adenomatoid tumor of the uterus. Am J Roentgenol. 2000;179(4):1068–70.
Konishi I, Fujii S, Mori T. Adenomatoid tumor of the uterus: a light and electron microscopic study of two cases. Asia Oceania J Obstet Gynaecol. 1984;10(3):385–91.
Lerias S, Ariyasriwatana C, Agaimy A, Erber R, Young RH, Oliva E. Adenomatoid tumor of the uterus: a report of 6 unusual cases with prominent cysts including 4 with diffuse myometrial involvement, 4 with uterine serosal involvement, and 2 presenting in curettage specimens. Int J Gynecol Pathol. 2021;40(3):248–56.
Livingston E, Guis MS, Pearl ML, Stern JL, Brescia RJ. Diffuse adenomatoid tumor of the uterus with serosal papillary cystic component. Int J Gynecol Pathol. 1992;11:288–92.
Luchs J, Diel J, Katz DS. Diffuse Adenomatoid Tumor of the Uterus. Am J Roentgenol. 2000;175(2):554–5.
Manucha V, Azar A, Shwayder JM, Hudgens JL, Lewin J. Cystic adenomatoid tumor of the uterus. J Cancer Res Ther. 2015;11(4):967–9.

Meng Q, Zeng Q, Wu X, Wan Q, Lei Y, Song T, et al. Magnetic resonance imaging and pathologic findings of 26 cases with uterine adenomatoid tumors. J Comput Assist Tomogr. 2015;39(4):499–505. Available from: www.jcat.org.
Mitsumori A, Morimoto M, Matsubara S, Yamamoto M, Akamatsu N, Hiraki Y. MR appearance of adenomatoid tumor of the uterus. J Comput Assist Tomogr. 2000;24(4):610–3. Available from: http://journals.lww.com/jcat.
Mizutani T, Yamamuro O, Kato N, Hayashi K, Chaya J, Goto N, et al. Renal transplantation-related risk factors for the development of uterine adenomatoid tumors. Gynecol Oncol Rep. 2016;1(17):96–8.
Nakayama H, Teramoto H, Teramoto M. True incidence of uterine adenomatoid tumors. Biomed Rep. 2013;1(3):352–4.
Nogales FF, Isaac A, Hardisson D, Bosincu L, Palacios J, Ordi J, et al. Adenomatoid tumors of the uterus: an analysis of 60 cases. Int J Gynecol Pathol. 2001;21:34–40.
Quick CM, Solomon DA. Adenomatoid Tumour. In: International Agency for Research on Cancer, editor. Female Genital Tumours, [Internet]. Lyon (France): International Agency for Research on Cancer; 2020. [cited 2022 Nov 30]. (WHO classification of tumours series, 5th ed.; vol. 4). Available from: https://tumourclassification.iarc.who.int/chapters/34.
Quigley JC, Hart WR. Adenomatoid tumors of the uterus. Am J Clin Pathol. 1981;76(5):627–35. Available from: http://ajcp.oxfordjournals.org/.
Ranjan R, Singh L, Nath D, Sable MN, Malhotra N, Bhatla N, et al. Uterine adenomatoid tumors: a study of five cases including three cases of the rare leiomyoadenomatoid variant. J Obstet Gynecol India. 2015;65(4):255–8.
Saran M, Sanghi A, Faruqi A. Adenomatoid tumour of the uterus presenting as a cyst. J Obstet Gynaecol (Lahore). 2007;27(6):637–8.
Soni V, Cahir-McFarland E, Kieff E. LMP1 TRAFficking Activates Growth and Survival pathways. In: TNF Receptor Associated Factors (TRAFs). 1st ed. New York: Springer New York; 2007. p. 173–87.
Srigley JR, Colgan TJ. Multifocal and diffuse adenomatoid tumor involving uterus and fallopian tube. Ultrastruct Pathol. 1988;12:351–5.
Stephenson TJ, Mills PM. Adenomatoid tumours: an immunohistochemical and ultrastructural appraisal of their histogenesis. J Pathology. 1986;148:327–35.
Tamura D, Maeda D, Halimi SA, Okimura M, Kudo-Asabe Y, Ito S, et al. Adenomatoid tumour of the uterus is frequently associated with iatrogenic immunosuppression. Histopathology. 2018;73(6):1013–22.
Tiltman A. Adenomatoid tumours of the uterus. Histopathology. 1980;4:437–43.
Wakita Y, Takahama J, Yamauchi S, Okada H, Marugami N, Itoh T, et al. Uterine adenomatoid tumor associated with lymph node lesions: a case report. Abdom Radiol. 2020;45(7):2263–7.
Yorita K, Tanaka Y, Hirano K, Kai Y, Arii K, Nakatani K, et al. A subserosal, pedunculated, multilocular uterine leiomyoma with ovarian tumor-like morphology and histological architecture of adenomatoid tumors: a case report and review of the literature. J Med Case Rep. 2016;10(1):352.
Young LA, Taylor HB. Adenomatoid tumors of the uterus and fallopian tube. Am J Clin Pathol. 1967;48(6):537–46.
Zapata JM, Martínez-García V, Lefebvre S. Phylogeny of the TRAF/MATH Domain. In: TNF Receptor Associated Factors (TRAFs). 1st ed. New York: Springer New York; 2007. p. 1–24.
Zhu S, Jin J, Gokhale S, Lu AM, Shan H, Feng J, et al. Genetic alterations of TRAF proteins in human cancers. Front Immunol. 2018;9:2111. Frontiers Media S.A.
Zotti T, Uva A, Ferravante A, Vessichelli M, Scudiero I, Ceccarelli M, et al. TRAF7 protein promotes Lys-29-linked polyubiquitination of IκB kinase (IKKγ)/NF-κB essential modulator (NEMO) and p65/RelA protein and represses NF-κB activation. J Biol Chem. 2011;286(26):22924–33.

Publisher's Note