

CORRECTION

Open Access



Correction to: Occurrence of metastatic eccrine porocarcinoma in an immunosuppressed patient

Mitul B. Modi^{1*}, Ata S. Moshiri², Toru Shoji³, Martin C. Mihm Jr⁴, Xiaowei Xu⁵ and David E. Elder⁵

Correction to: *Surg Exp Pathol* (2020) 3:16
<https://doi.org/10.1186/s42047-020-00068-x>

Following publication of the original article (Modi et al. 2020), we have been notified by the authors about the wrongly stated legends of Figs. 3 and 4. They Figures and legends should be presented as per below:

Author details

¹Department of Pathology and Laboratory Medicine, Pennsylvania Hospital of the University of Pennsylvania Health System, Philadelphia, PA, USA.

²Department of Medicine, Division of Dermatology, University of Washington, Seattle, WA, USA. ³Dianon Pathology, Shelton, CT, USA.

⁴Department of Dermatology, Harvard Medical School and Mihm Cutaneous Pathology Consultative Service, Boston, MA, USA. ⁵Department of Pathology and Laboratory Medicine and Dermatology, Hospital of the University of Pennsylvania, Philadelphia, PA, USA.

Published online: 06 January 2021

Reference

Modi MB et al (2020) Occurrence of metastatic eccrine porocarcinoma in an immunosuppressed patient. *Surg Exp Pathol* 3:16. <https://doi.org/10.1186/s42047-020-00068-x>

The original article can be found online at <https://doi.org/10.1186/s42047-020-00068-x>.

* Correspondence: mitul.modi7@gmail.com

¹Department of Pathology and Laboratory Medicine, Pennsylvania Hospital of the University of Pennsylvania Health System, Philadelphia, PA, USA
Full list of author information is available at the end of the article



© The Author(s). 2021 **Open Access** This article is licensed under a Creative Commons Attribution 4.0 International License, which permits use, sharing, adaptation, distribution and reproduction in any medium or format, as long as you give appropriate credit to the original author(s) and the source, provide a link to the Creative Commons licence, and indicate if changes were made. The images or other third party material in this article are included in the article's Creative Commons licence, unless indicated otherwise in a credit line to the material. If material is not included in the article's Creative Commons licence and your intended use is not permitted by statutory regulation or exceeds the permitted use, you will need to obtain permission directly from the copyright holder. To view a copy of this licence, visit <http://creativecommons.org/licenses/by/4.0/>.

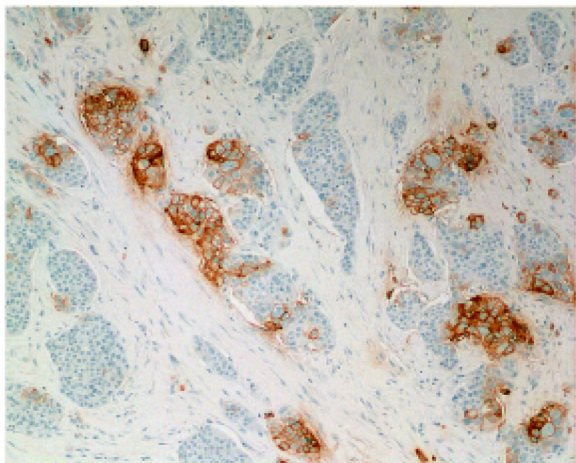


Fig. 3 Carcinoembryonic antigen (CEA) immunostain has a membranous pattern around a subset of tumor cells and highlights irregular ductal structures

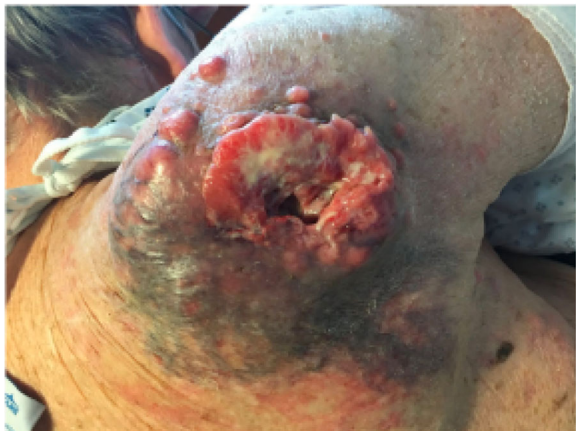

Fig. 4 Clinical image showing necrotic and fungating shoulder mass